

Brief Communications

Inhibition of Glutamate Transporters Results in a “Suppression-Burst” Pattern and Partial Seizures in the Newborn Rat

*Mathieu Milh, *Hélène Becq, †Nathalie Villeneuve, *Yehezkel Ben-Ari, and *Laurent Aniksztejn

*INMED/INSERM U29, Université de la Méditerranée, Marseille, France; and †Centre St-Paul—Hôpital Henri Gastaud, Marseille (France), Hôpital de la Timone, Service de Neurophysiologie Clinique, Marseille, France

Summary: *Purpose:* To determine the electrophysiological pattern and propose a clinical relevance of a deficient glutamate transport in the developing brain.

Methods: (a) Surface EEG-video monitoring in freely moving pups; (b) intracortical multiple unit activity (MUA) and local field potential recordings in 5- to 7-day-old rats after pharmacological inhibition of the glutamate transporters by DL-TBOA.

Results: Glutamate transporters inhibition alters the background cortical electrical activity inducing a dominant and persistent pattern of bilateral recurrent paroxysmal bursts alternating with periods of hypoactivity and also partial seizures.

Intracortical local field recordings show that paroxysmal bursts are associated with multiunits and gamma oscillations separated by periods of silence. This cortical activity involves the activation of ionotropic glutamate receptors and was not observed after kainate and pilocarpine administration.

Conclusions: We show that a dysfunction of glutamate transporters in immature rats leads to a singular cortical activity that is reminiscent of a “suppression-burst” pattern. We propose that an early deficiency of glutamate transport may underlie some early onset epilepsies. **Key Words:** Suppression-burst—Glutamate transporters—Animal model—EEG—Neonates.

A dysregulation of glutamate metabolism and homeostasis has been suspected to underlie many types of brain diseases including epilepsy (Kelly and Stanley, 2001). Thus, several studies have reported a high extracellular concentration of glutamate during and between ictal episodes in adult patients and animal models (Perry and Hansen, 1981; Danbolt, 2001). Particular attention has been focused on cell surface glutamate transporters i.e., the glial GLAST/EAAT1; GLT1/EAAT2, and the neuronal EAAC1/EAAT3 transporters since they represent the primary mechanism for glutamate clearance (Danbolt, 2001). Evidence for the implication of glutamate transporters in epilepsy came from studies performed in adult mice in which the gene encoding for GLT1 or GLAST was deleted or the EAAC1 protein eliminated, leading to epileptic seizures or increasing sensitivity to convulsive agents (Tanaka et al., 1997; Sepkuty et al., 2002). In contrast to adult, the role of glutamate transporters is much less documented during the neonatal period. This may

be of particular interest since the incidence of seizures is higher at this stage (Hauser et al., 1993) and seizures have very clear age dependency in their etiology, properties, electrophysiological phenotype, neurological and behavioral outcome (Baram and Hatalski, 1998; Holmes and Ben-Ari, 2001; Tharp, 2002). Immunohistochemical experiments have shown that neuronal and glial glutamate transporters are expressed in both human and rat brain during the fetal period (Bar-Peled et al., 1997; Furuta et al., 1997) and recent studies showed that inhibition of glutamate transporters leads to recurrent synchronized glutamate-mediated depolarizations in cortical pyramidal neurons from rat pups in vitro (Demarque et al., 2004). In order to dissect the consequences on electrographic patterns of a dysfunction of the glutamate transport in immature rat, we have performed surface EEG-video monitoring in freely moving and intracortical multiple unit activity (MUA) and local field potential recordings in P5–P7 old rat after pharmacological inhibition of the glutamate transporters by DL-TBOA (Shimamoto et al., 1998). This developmental period was chosen because it corresponds approximately to the perinatal period in Human brain (Baram and Hatalski, 1998; Khazipov et al., 2004), when most of early onset

Accepted April 26, 2006.

Address correspondence and reprint requests to Dr. Laurent Aniksztejn, INMED-INSERM U29, Parc Scientifique de Luminy BP13, 13273 Marseille Cedex 09, France. E-mail: anik@inmed.univ-mrs.fr
doi: 10.1111/j.1528-1167.2006.00839.x

epileptic encephalopathies begin (Nabbout and Dulac, 2003).

METHODS

All experiments were performed in vivo using post-natal days 5–7 (P5–P7) male Wistar rats born in our animal facilities. Procedures were performed in agreement with the European Union and French legislations concerning the animal care and use.

Video/EEG monitoring in freely moving rats

Injection of TBOA (kindly provided by Dr. Shimamoto, Osaka, Japan) was performed in rats anesthetized with halothane. The animal was placed in a stereotaxic frame, and 1 μ l of TBOA (5 mM/l) or saline solution was injected in the left lateral ventricle (ICV injection) with a needle via a peristaltic pump, during 4 min (250 nl/min; WPI) at stereotaxic coordinates adapted from the atlas of Paxinos (1991) anterior, -1 ; lateral, -1.8 ; deepness, -2.5 mm. Two 1 mm-long tungsten electrodes fixed to a copper plug (100 μ m diameter) were stereotaxically implanted 2 mm left and right from the bregma, at the surface of the cortex. A reference electrode was implanted 0.5 mm posterior to lambda, in the cerebellum. The electrodes were attached to the skull of the pup with glue and dental cement. Anesthesia was then stopped. After 5 min, rats were connected to a video-EEG system (Deltamed, France), in a 30°C room for a maximum of 6 h of recording. They were placed in a delimited area of 10 \times 10 cm² and were free during the whole recording. Two EEG signals were recorded, representing the difference of potential between the reference and the recording electrode (see Video). Signals were amplified (\times 1000), filtered at 0.16 Hz to 97 Hz pass, acquired at 256 Hz using a time constant of 0.3 seconds and analyzed using Coherence 3NT program (Deltamed, Paris, France). In some experiments, ketamine (2 mg/kg) or NBQX (15 mg/kg), to block, respectively, NMDA and AMPA receptors, were either injected intraperitoneally (IP) concomitantly to or 40 min after ICV injection of TBOA. In addition, some pups were recorded after IP injection of pilocarpine (360 mg/kg) or kainate (3 mg/kg). Scopolamine (1 mg/kg) was IP injected 30 min before the injection of pilocarpine in order to prevent peripheral effects of pilocarpine. At the end of the recording, rats were anaesthetized with chloral hydrate and sacrificed.

Intracortical MUA and local field potential recordings in anaesthetized rat pups

Intracortical extracellular recordings were obtained from anaesthetized neonatal rats. Two anchor bars were fixed to the skull under urethane anesthesia (1 g/kg). The head was then restrained by the skull bars and the body was surrounded by a cotton nest, mimicking the presence of littermates. Recordings were performed using coated tungsten wires (20 μ m in diameter) in the left somatosen-

sory cortex (2 mm left from the bregma, 800 μ m deep, see Khazipov et al., 2004). For simultaneous recording of field potential and multiunit activity, tungsten wires (50 μ m in diameter) were used. Body temperature of the pups was continuously monitored and was kept between 34°C and 37°C. After an hour of control recording period, 1 μ l of saline solution or TBOA was injected in the left lateral ventricle.

Data were acquired at a sampling rate of 10 kHz and analyzed off-line. Bursts of multiunits were detected from the discriminated spike trains. We considered that multiunits occurred in a burst if they occurred in a group of at least five spikes within a period that lasted less than 1 s. For each burst, amplitude was defined as the amplitude of the largest event of the burst.

RESULTS AND DISCUSSION

DL-TBOA was used to reduce the activity of the main glutamate transporters present in the cortex: the neuronal EAAC1 and glial GLT1, GLAST transporters (Furuta et al. 1997). TBOA has several advantages as compared to other glutamate transporters inhibitors: (i) it is a non-transportable inhibitor and as such does not induce an artificial transmitter release through hetero exchange, (ii) it does not act as a partial agonist for glutamate receptors as demonstrated by electrophysiological recordings and binding assays (Shimamoto et al., 1998; Jabaudon et al., 1999; Demarque et al., 2004).

Blockade of glutamate transporters leads to bilateral recurrent bursts of spikes alternating with periods of silence

Video/EEG recording was first performed in non-injected animals (control rats, $n = 5$) or animals that received an ICV injection of ACSF (sham rats, $n = 5$). In both cases, EEG was characterized by the occurrence of bilateral epochs of slow delta waves every 10–40 s, lasting 1–7 s, superimposed with faster alpha oscillations (9.8 ± 2.3 Hz, pooled data of 10 animals, Fig. 1A). Between these episodes, the activity was low in both amplitude and frequency (Fig. 1A). In contrast, EEG in TBOA-treated animals ($n = 8$) was characterized by the occurrence of bilateral recurrent bursts consisting in a slow deflection followed by fast spiking activity (19.04 ± 1.5 Hz) and alternating with periods of absence of any detectable activity (Fig. 1B). These paroxysmal bursts occurred at a regular rate in each animal (0.017 ± 0.002 Hz, $n = 8$), lasted 10 ± 3 s and were (40% of cases) or not associated with a single or 2–3 myoclonic startles (see Video). Long-lasting rhythmic delta–theta oscillatory activities were also recorded (frequency : 4–12 per hour, duration 48 ± 20 s (Fig 1C, $n = 8$). They independently involved either the ipsilateral (60%) or the contralateral hemisphere from the injection site (40%) and could occasionally be associated with behavioral manifestations such as crawling, tonic

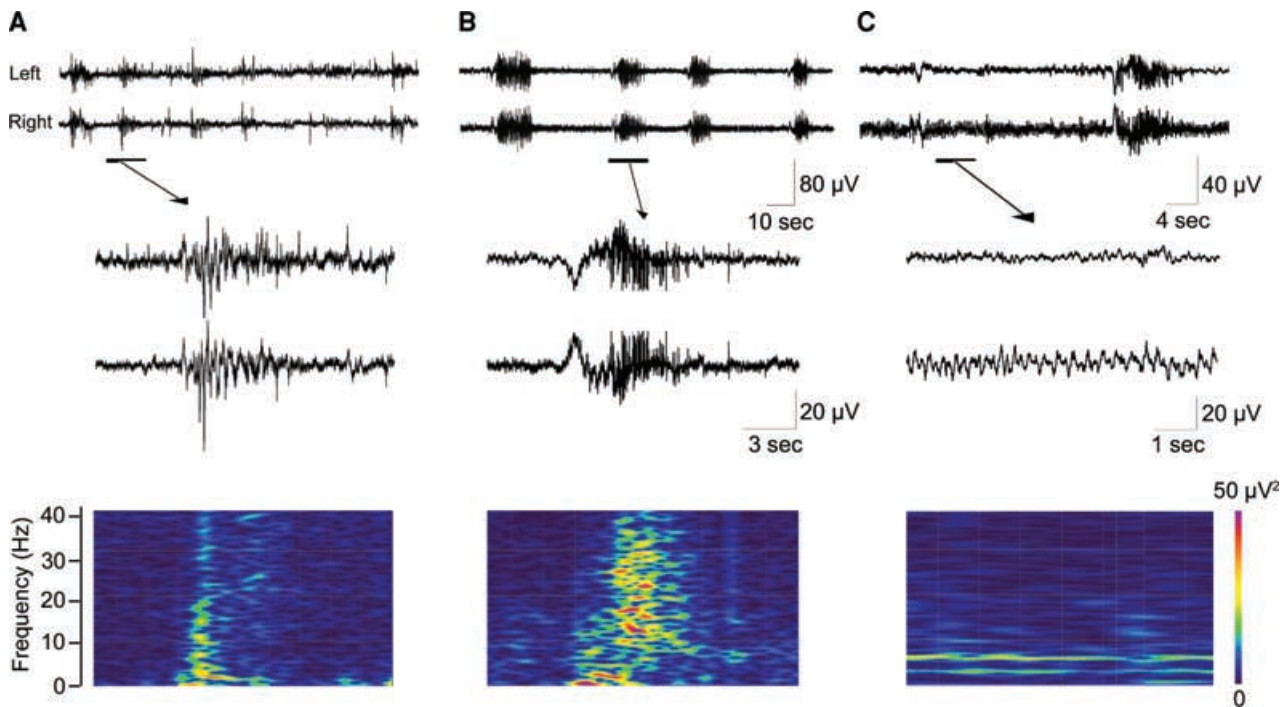


FIG. 1. Inhibition of glutamate transporters imposes a singular EEG pattern of recurrent bilateral paroxysmal bursts of spikes and partial seizures. **(A)** Simultaneous recording of left (ipsilateral from the injection site) and right somatosensory cortex in a freely moving rat pup (P5) after ACSF injection (sham rat). An example is shown at higher resolution scale below with the corresponding wavelet analysis. **(B)** After ICV injection of TBOA, the EEG shows recurrent bursts of fast spiking activities that are mostly preceded by an initial slow wave. An example is shown below at a higher time resolution with the corresponding wavelet analysis. **(C)** Partial seizures characterized by long lasting delta-theta unilateral oscillations are also recorded (on the right side i.e., contralaterally from the injection site) after TBOA injection.

posture of one or two limbs, freezing-like posture, hypermotor activity. This latter activity is reminiscent of partial seizures that are mostly characterized by rhythmic slow oscillations in one territory of the brain probably due to poor axonal myelination (Hamano et al., 1998) and mostly associated with nonspecific behavior in human neonates at this developmental stage (Tharp, 2002; Patrizi et al., 2003).

Both paroxysmal bursts and partial seizures could be observed up to 6 h after the injection. Therefore inhibition of glutamate transporters leads to an EEG pattern characterized by discontinuous paroxysmal burst alternating with period of silence and partial seizures.

To further characterize changes produced by TBOA on cortical activity and to confirm the absence of any background activity between paroxysmal bursts, we used micro-electrodes to record local field and multiunits within the somatosensory cortex (Khazipov et al., 2004), before and after ICV injection of TBOA in the same restrained animal. This electrophysiological artifact-free approach allows to record the activity of a population of cells but also to detect unitary spike of neurons. The field activity in control conditions or after ICV injection of ACSF was similar and characterized by intermittent beta–delta oscillations (12.6 ± 2.3 Hz, $n = 10$ animals) (Fig. 2A, B). These oscillations are reminiscent of spindle bursts de-

scribed previously (Khazipov et al., 2004). The oscillations were associated with multiunit activity (Fig. 2A, D). About 20% of MUA occurred between the oscillations. ICV injection of TBOA led to deep modification of the cortical activity that displayed recurrent negative deflections superimposed with gamma oscillations (34 ± 0.85 Hz, $n = 7$ rats) followed by beta–gamma oscillations (26 ± 0.25 Hz, $n = 7$ animals, Figs. 2 A–C). Virtually all the MUA were recorded within paroxysmal bursts, and there was no remaining activity between the bursts ($79 \pm 3.6\%$ of MUA within cortical events in control versus $94 \pm 1\%$ in TBOA-treated animal, $p < 0.01$, $n = 7$, paired t-test, not shown; Fig. 2D, see also Fig. 3B). Compared to control, these network oscillations occurred at a higher frequency rate, the average duration was longer (Fig. 2 E, F) and there was a 204% increase in the number of MUA per bursts ($p < 0.01$, paired t-test; not shown). No remaining normal oscillations could be recorded. Therefore we confirm that pharmacological blockade of glutamate transporters generates recurrent paroxysmal bursts without any remaining activity between them. These paroxysmal bursts involved the activation of glutamate receptors since their frequency and duration were significantly decreased by administration of NMDA antagonist ketamine ($n = 4$) or AMPA antagonist NBQX ($n = 4$) (see Methods, Figs. 2E–G).

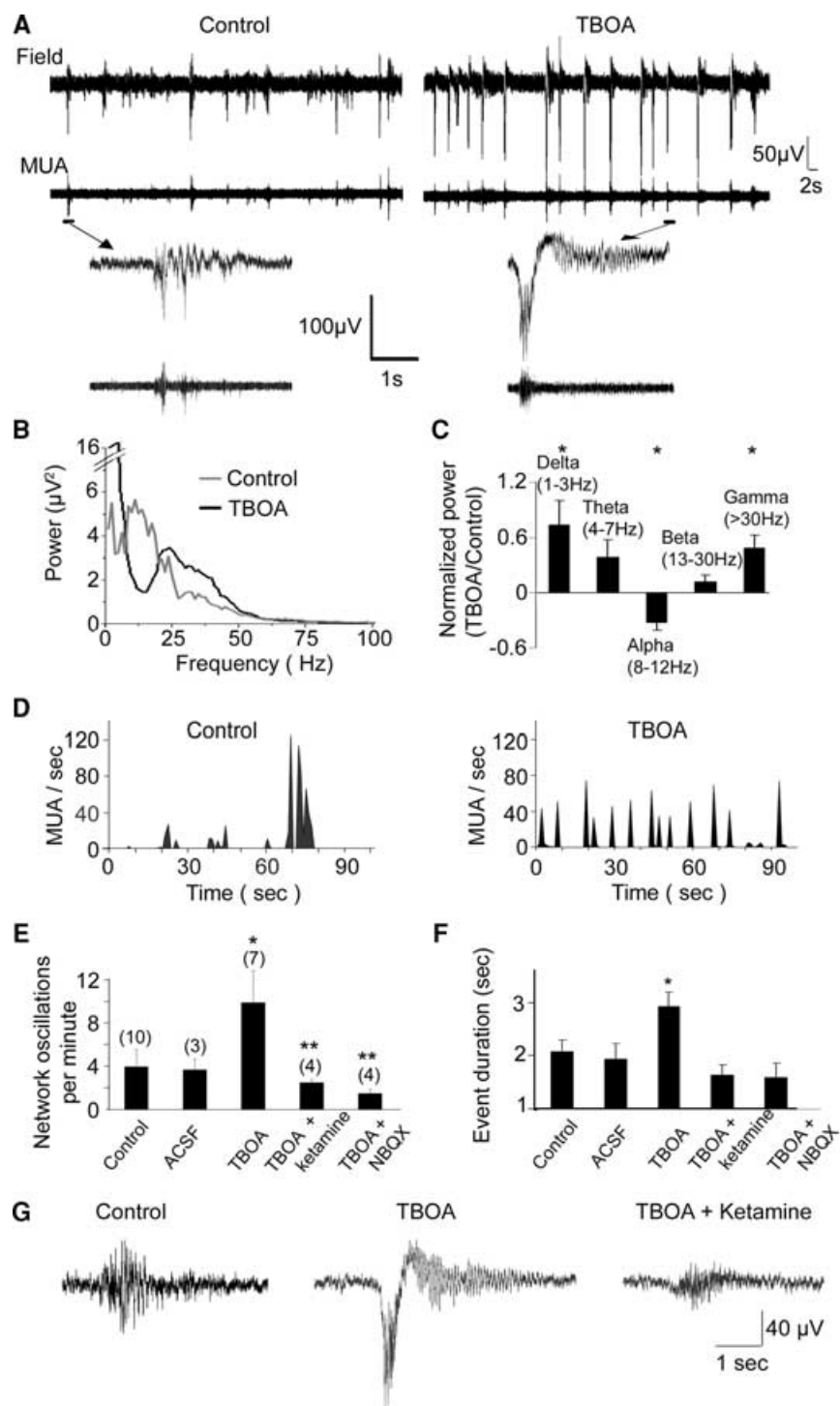


FIG. 2. Recurrent paroxysmal bursts are associated with increased multiunit activity and separated by silent periods. **(A)** Simultaneous recordings of the extracellular field potential (upper trace) and multiple unit activity (MUA) in the left somatosensory cortex (unilaterally from the injection site) of a 5-day-old rat, before and after ICV injection of TBOA. Representative examples are shown below. **(B)** Pooled average power spectrum of control versus post-TBOA bursts ($n = 7$ pups). **(C)** Normalized ratio of the average power spectrum after versus before TBOA injection. Asterisks indicate a significant difference versus control ($p < 0.05$). **(D)** Frequency histogram of MUA before (left) and after (right) blockade of glutamate transporters in one representative example. Note that after TBOA administration, unitary discharges were more frequent but discontinuous. Frequency **(E)** and duration **(F)** of events in control ($n = 10$), sham, TBOA treated, and after IP injection of glutamate receptor antagonists Ketamine and NBQX, showing that paroxysmal bursts involve NMDA and AMPA receptors activation. Number of animal are given in brackets. *and ** indicate a significant difference versus control and TBOA, respectively ($p < 0.05$ paired t-test). **(G)** Representative examples of oscillations in the same animal before (left), after injection of TBOA (middle) and ketamine (right).

Video/EEG pattern observed with other convulsive agents

In order to determine whether a discontinuous pattern could be seen with other convulsive agents, we performed same recordings in pups treated by IP injection of kainate ($n = 3$) or pilocarpine ($n = 3$) (see Methods) known to generate seizures *in vivo* (Tremblay et al., 1984; Priel et al., 1996). Pilocarpine induced activities that consisted

in continuous beta–gamma oscillations and bursts of large amplitude, without any period of silence (Figs. 3 A–C). In freely moving animals, pilocarpine induced recurrent ictal discharges made of oscillatory activity in the beta–gamma band, associated with head bobbing during 20–30 min after which the EEG returned to a pattern of activity that was not different from sham animals (Fig. 3D). Similar results were obtained after kainate injection (Fig. 3E; see also

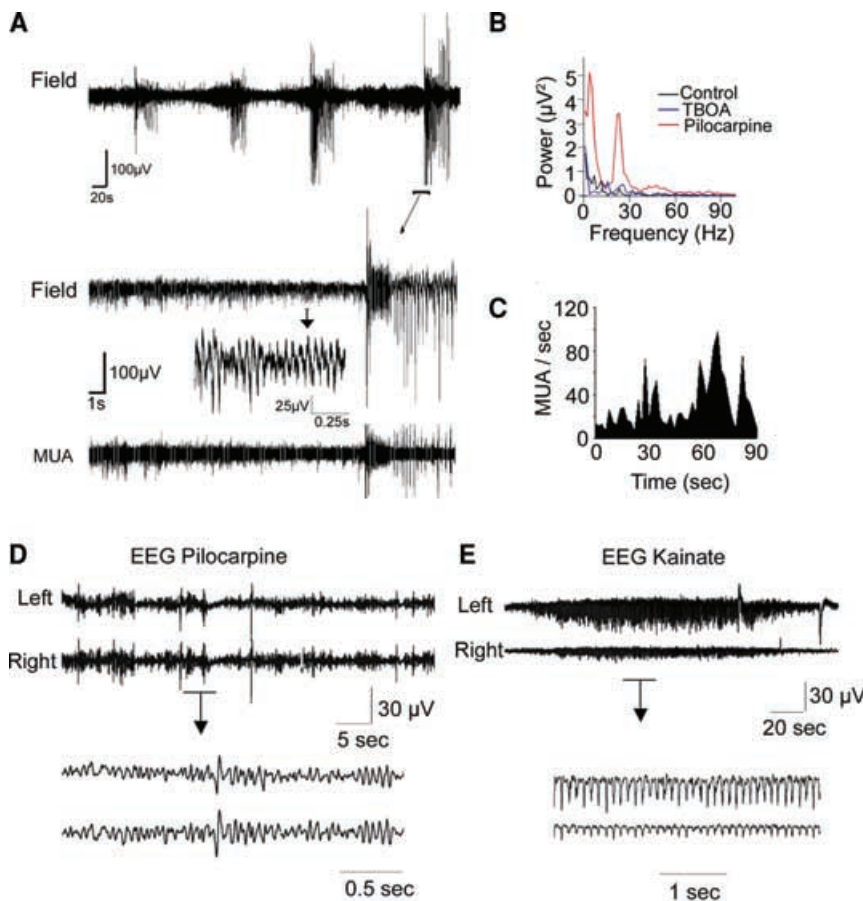


FIG. 3. Pilocarpine or kainate do not generate a “suppression burst” pattern. **(A).** Field and MUA recordings from a P5 rat after IP injection of pilocarpine. Pilocarpine induces continuous beta oscillation and recurrent bursts. There is no silent period between bursts. At higher time resolution (below), note that multiple unit activities are continuously present between bursts. **(B).** Average power spectrum between recurrent bursts in control, and after TBOA or pilocarpine treatment. Note the presence of beta activity after pilocarpine injection, whereas there is no remaining activity between the bursts in control or after TBOA treatment. **(C).** MUA frequency in pilocarpine-treated animals: periods of silence could not be recorded (compare with Fig. 2D). **(D, E)** EEG recordings in freely moving animals treated with pilocarpine **(D)** or kainate **(E)**: long-lasting episodes of rhythmic oscillations without any silent period are observed.

Dzhala et al., 2005). We never observed recurrent bursts of paroxysmal activity alternating with periods of silence.

In conclusion, a deficit in glutamate transport in the developing brain leads to a singular pattern of recurrent paroxysmal bursts alternating with periods of silence and no remaining normal background activity. To the best of our knowledge, this pattern has never been described in other animal models of epilepsy during the neonatal period.

The mechanisms involved in the generation of this pattern remain to be determined. In a previous study performed *in vitro* in neocortical slices (Demarque et al., 2004), we observed that the inhibition of glutamate transporters led to recurrent synchronizations of the neuronal activity that was reflected by periodic cell depolarizations and bursts of action potentials. We have provided experiments suggesting that this oscillatory pattern was triggered by a cyclic modulation of glutamate levels in the extracellular space by a mechanism that probably involves a periodic pattern of glutamate release by cortical cells unmasked after glutamate transporters inhibition. We propose that this process may underlie the pattern observed *in vivo*.

This cortical activity is reminiscent of “suppression burst.” The EEG pattern is characterized by the occur-

rence of high-amplitude bursts of spikes and slow waves alternating with almost silent periods, and by the absence of normal background activity (Aicardi, 1985). Such pattern has been found in some early onset epileptic encephalopathies, including early myoclonic encephalopathy (Aicardi, 1985; Schlumberger et al., 1992; Ohtahara and Yamatogi, 2003). Partial seizures are also reported. Its pathophysiology remains elusive and morphological abnormalities of the brain are rarely reported (Aicardi, 1985; Schlumberger et al., 1992; Sharp, 2002; Ohtahara and Yamatogi, 2003). Interestingly, a mutation in a gene encoding for a mitochondrial glutamate transporter has been recently reported in two related patients who suffered from early onset epilepsy with suppression burst (Molinari et al., 2005). This mutation has been shown to impair the mitochondrial glutamate import, leading to an increased pool of the transmitter in the cytosol (Molinari et al., 2005). Because cell-surface glutamate transporters are powered by transmembrane gradients of Na^+ , K^+ , H^+ and substrate, an intracellular accumulation of glutamate may prevent or reduce its transport from the extracellular to the intracellular space thus mimicking the action of TBOA (Barbour et al., 1991; Danbolt, 2001). Although the clinical relevance of our study to this severe epileptic disorder requires further investigations, our data suggest

that a deficient transport of glutamate may be a potential cause for early onset epilepsy, most likely those associated with a suppression-burst pattern.

Acknowledgments: We acknowledge the Fondation Française pour la Recherche sur l'Epilepsie (FFRE) and la Société de Soin pour les Enfants Paralysés et Polymalformés (SESEP) for financial support. We are extremely grateful to Dr. Rustem Khazipov for the precious help in the organization of the experimental set-up and help in data analysis. We would like to thank Dr. Olivier Dulac, Dr. Perrine Plouin, Dr. Catherine Chiron, Dr. Rosa Cossart, and Dr. Alfonso Represa for helpful discussion.

REFERENCES

- Aicardi J. (1985) Early myoclonic encephalopathy. In Roger J, Bureau M, Dravet C, Dreyfus FE, Perret A, Wolf P (Eds) *Epileptic syndromes in infancy, childhood and adolescence*. John Libbey, London, pp. 12–21.
- Baram TZ, Hatalski CG. (1998) Neuropeptide-mediated excitability: a key triggering mechanism for seizure generation in the developing brain. *Trends in Neurosciences* 21:471–476.
- Barbour B, Brew H, Attwell D. (1991) Electrogenic uptake of glutamate and aspartate into glial cells isolated from the salamander (*Ambystoma*) retina. *Journal of Physiology* 436:169–193.
- Bar-Peled O, Ben Hur H, Biegon A, Groner Y, Dewhurst S, Furuta A, Rothstein JD. (1997) Distribution of glutamate transporter subtypes during human brain development. *Journal of Neurochemistry* 69:2571–2580.
- Danbolt NC. (2001) Glutamate uptake. *Progress in Neurobiology* 65:1–105.
- Demarque M, Villeneuve N, Manent JB, Represa A, Ben-Ari Y, Anikstejn L. (2004) Glutamate transporters prevent the generation of seizures in the developing rat neocortex. *Journal of Neurosciences* 24:3289–3294.
- Dzhala VI, Talos DM, Sdrulla DA, Brumback AC, Mathews GC, Benke TA, Delpire E, Jensen FE, Staley KJ. (2005) NKCC1 transporter facilitates seizures in the developing brain. *Nature Medicine* 11:1205–1213.
- Furuta A, Rothstein JD, Martin LJ. (1997) Glutamate transporter protein subtypes are expressed differentially during rat CNS development. *Journal of Neuroscience* 17:8363–8375.
- Hamano K, Takeya T, Iwasaki N, Nakayama J, Ohto T, Okada Y. (1998) A quantitative study of the progress of myelination in the rat central nervous system, using the immunohistochemical method for proteolipid protein. *Brain Research Developmental Brain Research* 108:287–293.
- Hauser WA, Annegers JF, Kurland LT. (1993) Incidence of epilepsy and unprovoked seizures in Rochester, Minnesota: 1935–1984. *Epilepsia* 34:453–468.
- Holmes GL, Ben Ari Y. (2001) The neurobiology and consequences of epilepsy in the developing brain. *Pediatric Research* 49:320–325.
- Jabaudon D, Shimamoto K, Yasuda-Kamatani Y, Scanziani M, Gähwiler BH, Gerber U. (1999) Inhibition of uptake unmasks rapid extracellular turnover of glutamate of nonvesicular origin. *Proceedings of National Academy of Sciences USA* 96:8733–8738.
- Kelly A, Stanley CA. (2001) Disorders of glutamate metabolism. *Mental Retardation and Developmental Disabilities Research Reviews* 7:287–295.
- Khazipov R, Sirota A, Leinekugel X, Holmes GL, Ben Ari Y, Buzsáki G. (2004) Early motor activity drives spindle bursts in the developing somatosensory cortex. *Nature* 432:758–761.
- Molinari F, Raas-Rothschild A, Rio M, Fiermonte G, Encha-Razavi F, Palmieri L, Palmieri F, Ben Neriah Z, Kadhom N, Vekemans M, Attie-Bitach T, Munnich A, Rustin P, Colleaux L. (2005) Impaired mitochondrial glutamate transport in autosomal recessive neonatal myoclonic epilepsy. *American Journal of Human Genetics* 76:334–339.
- Nabbout R, Dulac O. (2003) Epileptic encephalopathies: a brief overview. *Journal of Clinical Neurophysiology* 20:393–397.
- Ohtahara S, Yamatogi Y. (2003) Epileptic encephalopathies in early infancy with suppression-burst. *Journal of Clinical Neurophysiology* 20:398–407.
- Patrizi S, Holmes GL, Orzalesi M, Allemand F. (2003) Neonatal seizures: characteristics of EEG ictal activity in preterm and full-term infants. *Brain Development* 25:427–437.
- Paxinos G. (1991) *Atlas of the developing rat brain*. Acad Press INC, Harcourt Brace Jovanovich Publishers, San Diego.
- Perry TL, Hansen S. (1981) Amino acid abnormalities in epileptogenic foci. *Neurology* 31:872–876.
- Priel MR, Dos Santos NF, Cavalheiro EA. (1996) Developmental aspects of the pilocarpine model of epilepsy. *Epilepsy Research* 26:115–121.
- Schlumberger E, Dulac O, Plouin P. (1992) Early infantile epileptic syndrome(s) with suppression-burst: nosological considerations. In Roger J, Bureau M, Dravet C, Dreifuss FE, Perret A, Wolf P (Eds) *Epileptic syndromes in infancy, childhood and adolescence*. 2nd ed. John Libbey, London, pp. 35–45.
- Sepkuty JP, Cohen AS, Eccles C, Rafiq A, Behar K, Ganel R, Coulter DA, Rothstein JD. (2002) A neuronal glutamate transporter contributes to neurotransmitter GABA synthesis and epilepsy. *Journal of Neurosciences* 22:6372–6379.
- Shimamoto K, Lebrun B, Yasuda-Kamatani Y, Sakaitani M, Shigeri Y, Yumoto N, Nakajima T. (1998) DL-threo-beta-benzoyloxyaspartate, a potent blocker of excitatory amino acid transporters. *Molecular Pharmacology* 53:195–201.
- Tanaka K, Watase K, Manabe T, Yamada K, Watanabe M, Takahashi K, Iwama H, Nishikawa T, Ichihara N, Kikuchi T, Okuyama S, Kawashima N, Hori S, Takimoto M, Wada K. (1997) Epilepsy and exacerbation of brain injury in mice lacking the glutamate transporter GLT-1. *Science* 276:1699–1702.
- Tharp BR. (2002) Neonatal seizures and syndromes. *Epilepsia* 43(Suppl 3):2–10.
- Tremblay E, Nitecka L, Berger ML, Ben Ari Y. (1984) Maturation of kainic acid seizure-brain damage syndrome in the rat. I. Clinical, electrographic and metabolic observations. *Neuroscience* 13:1051–1072.

Video.

Simultaneous video-EEG recording of a 5-day-old rat, 1 h after ICV injection of TBOA. The video shows a bilateral paroxysmal burst that begins with an initial slow wave followed by burst of spikes. The EEG is associated with myoclonic startles.